

## **Correlations between shearwave elastography of thyroid nodules and cytological data: study about 157 patients**

**Poster No.:** C-1236

**Congress:** ECR 2011

**Type:** Scientific Exhibit

**Authors:** H. Monpeyssen<sup>1</sup>, J.-M. Correas<sup>1</sup>, J. Tramalloni<sup>1</sup>, S. Poiree<sup>1</sup>, N. Voillemot<sup>1</sup>, J. P. Jais<sup>1</sup>, O. Hélénon<sup>2</sup>; <sup>1</sup>Paris/FR, <sup>2</sup>Paris, Cédex 15/FR

**DOI:** 10.1594/ecr2011/C-1236

Any information contained in this pdf file is automatically generated from digital material submitted to EPOS by third parties in the form of scientific presentations. References to any names, marks, products, or services of third parties or hypertext links to third-party sites or information are provided solely as a convenience to you and do not in any way constitute or imply ECR's endorsement, sponsorship or recommendation of the third party, information, product or service. ECR is not responsible for the content of these pages and does not make any representations regarding the content or accuracy of material in this file.

As per copyright regulations, any unauthorised use of the material or parts thereof as well as commercial reproduction or multiple distribution by any traditional or electronically based reproduction/publication method is strictly prohibited.

You agree to defend, indemnify, and hold ECR harmless from and against any and all claims, damages, costs, and expenses, including attorneys' fees, arising from or related to your use of these pages.

Please note: Links to movies, ppt slideshows and any other multimedia files are not available in the pdf version of presentations.

[www.myESR.org](http://www.myESR.org)

# Purpose

The correlation between a nodule stiffness and malignancy has been found by clinical palpation and demonstrated in

in vitro studies. Ultrasound Elastography (USE) is able to provide stiffness informations and is used since 2005 in thyroid nodule examination. The first studies indicated clearly that USE can significantly improve ultrasound (US) diagnostic value for the identification of malignant thyroid nodules. They concerned static (or strain) elastography but the clinical routine use is suffering from limitations. Quantification might be able to reduce inter and intra observer variability.

ShearWave elastography (SWE) is becoming available and provides true quantitative measurement of stiffness with reduced variability between operators. The purpose of our study was to evaluate SWE in routine clinical practice.

SWE provides results in a color box and Region-of-Interest (ROI) can be positioned over the normal thyroid parenchyma and the nodule to measure the stiffness of each tissue. The mean stiffness, min, max and standard deviation (sd) values are calculated for each ROI. The ratio between the two ROI is automatically calculated.

## Images for this section:

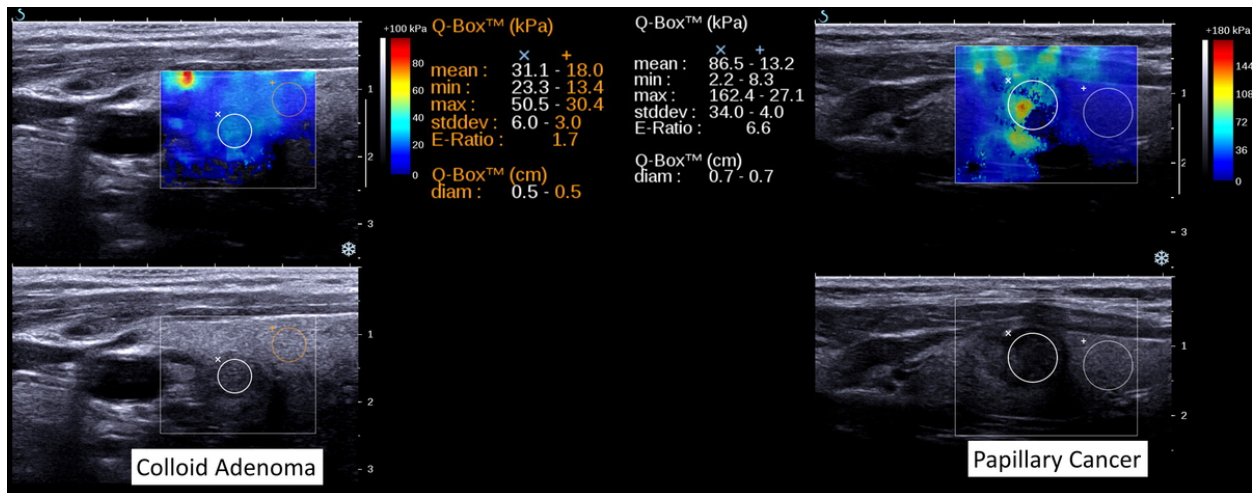


Fig. 1: SWE in Benign Nodule and Papillary Cancer.

## Methods and Materials

Methods and patients: 195 patients were referred for thyroid US. In this population, 157 patients were presenting with one or more thyroid nodules. A total of 161 thyroid nodules were studied using conventional US examination (MyLab Gold, Easote, Genova, Italy) and SWE elastography (Aixplorer, Supersonic Imagine, Aix-en-Provence, France) with a high frequency linear transducer. Nodule stiffness and ratio were calculated. Cytological correlations were obtained in all cases using fine needle aspiration (FNAB). In addition, histological confirmation of cancer was obtained in case of suspicious cytological findings. Exclusion measurement criteria included the incomplete signal detection within the ROI, reduced field of view yielding to impossible simultaneous measurement of normal parenchyma and nodule, artifacts due to excessive pressure.

## Results

Results: SWE measurements from 32 nodules were finally excluded during the review process, corresponding to the learning curve. Statistical calculations were performed from the 129 nodules included.

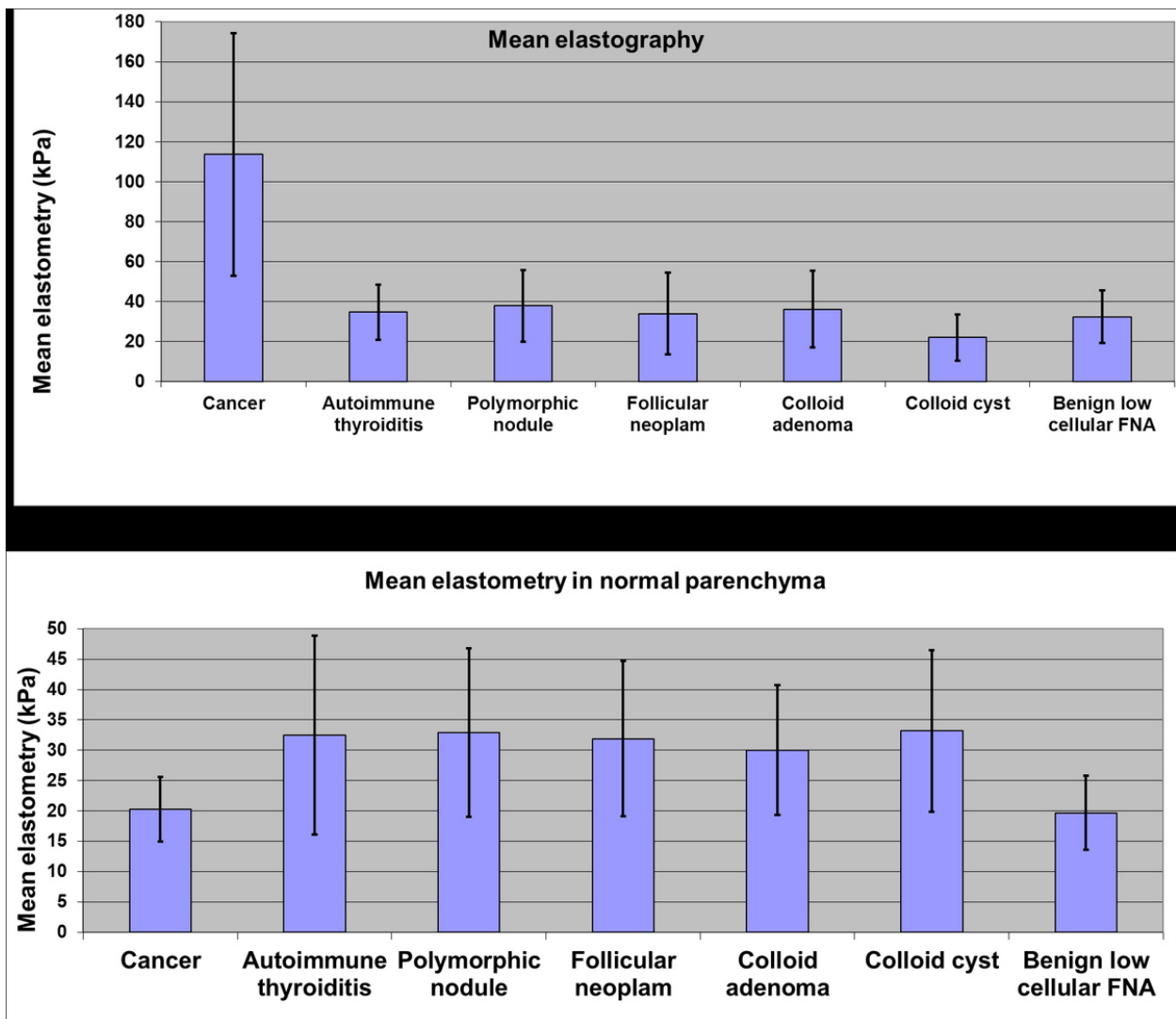
The stiffness of the embedding tissue was not significantly different between all the categories.

Cancers exhibited a significant increased stiffness ( $114 \pm 61$  kPa) compared to normal parenchyma ( $31 \pm 12$  kPa) and other nodules ( $34 \pm 17$  kPa). The ratio between cancers and parenchyma was significantly higher ( $p < 0.001$ ).

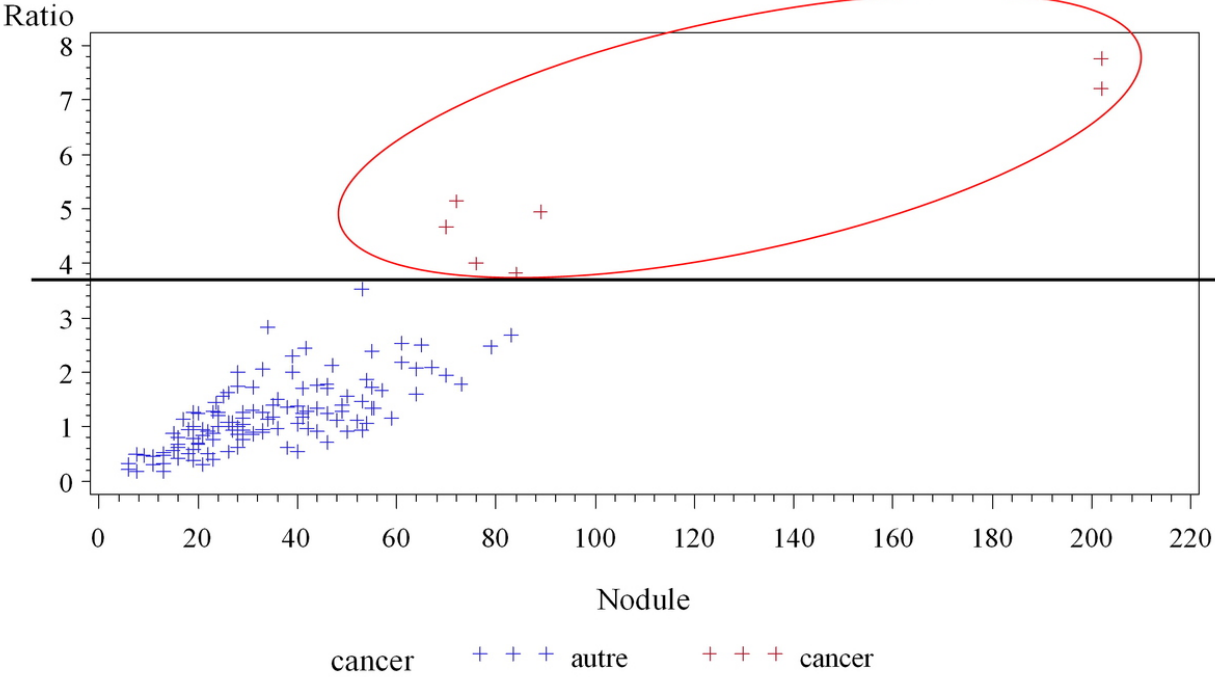
**Images for this section:**

	n	mean ratio	mean stiffness	sd	min	max	mean normal
cancer	7	5.40	113.6	60.8	70	202	20.3
thyroiditis	14	1.22	34.6	13.8	15	55	32.5
polymorphic	20	1.23	37.8	18	13	64	32.9
follicular neoplasm	9	1.17	33.9	20.4	6	59	31.9
colloid adenoma	60	1.27	34.9	17.06	9	83	29.1
rich colloid adenoma	6	0.74	21.9	11.7	6	41	33.2
benign low cellularity	11	0.95	32.3	13.2	8	50	19.6
acellular	2	1.51	34.2	37.8	7	61	20.6

Fig. 1: SWE data for each cytological group



**Fig. 2:** Mean stiffness in nodules and embedding tissues



**Fig. 3:** Stiffness ratio between cancers and benign nodules

## Conclusion

Conclusion: ShearWave Elastography can provide additional information to the clinician to diagnose thyroid malignancy, and direct FNAB to the most suspicious lesions. It is an easy and promising imaging technique for characterization of thyroid nodules. Multicentric study remains necessary to confirm these data.

## References

### **Shear wave elastography: a new ultrasound imaging mode for the differential diagnosis of benign and malignant thyroid nodules**

[Sebag F, Vaillant-Lombard J, Berbis J, Griset V, Henry JF, Petit P, Oliver C.](#)

J Clin Endocrinol Metab. 2010 Dec;95(12):5281-8.

## Personal Information

Herve Monpeyssen, MD, is a thyroidologist in Versailles (France). He also works in the Adult Unit of Radiology at Necker Hospital Paris (research), and in the Department of Nuclear Medicine at Pitié-Salpêtrière Hospital (Paris). He has worked for the past few years at the American Hospital in Paris. He is board certified in both Endocrinology and ultrasound examination. Since 2004, he has worked exclusively in thyroid and parathyroid areas. Dr Monpeyssen combines neck ultrasound examinations (3000 per year) with clinical practice and carries out a yearly average of 1200 ultrasound guided aspirations for cytology.

His main fields of interest are thyroid cancers, thyroid dysfunctions (especially Grave's disease), parathyroid adenomas, and thyroid elastography (strain with quantification and ShearWaves) and has given many speeches on this last topic.

In addition to his clinical practice, he is an active teacher in thyroid ultrasound examination for the "Diplome National Inter-Universitaire d'Echographie (National Inter-University Degree of Ultrasound Scan)" (Pr Leenhardt, Director), and in the "Ateliers de Radiologie" (Radiology Workshops) at Necker Hospital in Paris (Pr Helenon, Director).

Dr Monpeyssen is a member of the European Thyroid Association, the European Society of Radiology, the French Endocrine Society and French Radiological Society and of the French Thyroid Research Group.

He has published several articles in French Journals of Endocrinology and Radiology and has written a number of chapters in books on imaging. With Dr Jean Tramalloni, he wrote the book "Echographie de la thyroïde" (Ultrasound Examination of the Thyroid) (Masson Ed 2005). He is a reviewer of imaging articles in the European Journal of Endocrinology and in the Journal of Clinical Ultrasound and gives talks in french and international congresses (RSNA, Euroson, European Congress of Radiology and International Thyroid Congress).

[hm-thyroide@wanadoo.fr](mailto:hm-thyroide@wanadoo.fr)